

## Minimising iatrogenic nerve injury in primary care

Nerve injuries usually present as pain, numbness, or weakness, and can have devastating consequences for patients. Procedures that are common in primary care can cause nerve injury. Iatrogenic nerve injuries are largely preventable by understanding nerve anatomical course and surface anatomy, and the risky interventions and regions. Most knowledge of nerve anatomical course is derived from early work on cadaver dissection, but modern imaging techniques more accurately map nerve anatomical course in living bodies.

We provide an overview of nerve injuries in primary care, discuss updated nerve anatomical course and surface anatomy based on modern radiological evidence, and make recommendations to guide safer interventions in primary care.

### NERVE INJURIES IN PRIMARY CARE

In New Zealand's primary care treatment injury claims dataset there were 69 nerve injuries over 4 years (2% of primary care injuries).<sup>1</sup> Venepuncture was the leading cause of nerve injury (27; 39%), followed by intramuscular injection (17; 25%), and steroid injection (15; 22%). Venepuncture injured the cutaneous nerve of the forearm (14), and the median (9) and radial (4) nerves; intramuscular injections injured the sciatic (11), lateral cutaneous (3), and axillary (3) nerves; steroid injections injured the median (12, carpal tunnel) and ulnar (3, medial epicondyle) nerves; intravenous cannulation in the forearm injured the superficial radial nerve (4); and minor surgical procedures injured the spinal accessory (3), common fibular (1), sural (1), and ilioinguinal nerves (1). Most nerve injuries were minor, but 17 (25%) were assessed as having major or serious potential consequences. These severe injuries were caused by steroid injections (9), intramuscular injections (4), minor surgery (3), and venepuncture (1). There were no claims for nerve injuries in patients younger than 17 years old.

### NERVE ANATOMICAL COURSE

#### Sciatic nerve in the gluteal region

Sciatic nerve injury in the buttock may result in numbness, and weakness of the hamstrings and all muscles below the knee. The upper outer quadrant of the buttock (dorsogluteal region) remains one of the most common sites for intramuscular injection worldwide.<sup>2</sup> Recent cross-sectional imaging studies in living adults and children have led to a revision of the surface anatomy of the sciatic nerve.<sup>3</sup> This evidence suggests that the safe zone for injection is not the upper outer buttock but the gluteal triangle (ventrogluteal region). The gluteal triangle is located by placing the palm of the opposing hand on the greater trochanter and the index finger on the anterior superior iliac spine, forming a triangle with the middle finger pointing towards the iliac crest, as demonstrated in Figure 1.<sup>3</sup> The recommended injection site is the centre of the triangle with the needle inserted at 90° to the skin surface. Supplementary material in the form of short educational videos on nerve anatomy to guide safer interventions in primary care are available on request from authors.

#### Axillary nerve in the deltoid region

Damage to the axillary nerve can result in shoulder abduction weakness and numbness.<sup>4</sup> Many immunisation guidelines recommend that the anterolateral thigh be used for intramuscular injection in infants, and the deltoid region or anterolateral thigh in older children. However, current anatomical knowledge suggests that the deltoid region is problematic because of the highly variable anatomical course of the axillary nerve.<sup>4</sup> Given readily accessible alternative injection sites, the deltoid region is best avoided for intramuscular injection. If selected, the safest zone is the lateral aspect no more than 4 cm below the lower border of the acromion.<sup>5</sup>

Modern radiological evidence suggests that the safest sites for intramuscular

**KA Wallis**, MBHL, PhD, FRNZCGP, DipObst, senior lecturer, Department of General Practice and Primary Health Care; **SA Mirjalili**, PhD, MD, PGDipSurg, PGCertCPU, PGDipSci, senior lecturer, Department of Anatomy and Medical Imaging, University of Auckland, Auckland.

**T Hills**, MSc, DPhil, registrar, Department of Medicine, Auckland Hospital, Auckland.

#### Address for correspondence

S Ali Mirjalili, Department of Anatomy and Medical Imaging, University of Auckland, Grafton 505/185, 85 Park Rd, Auckland 1023, New Zealand.

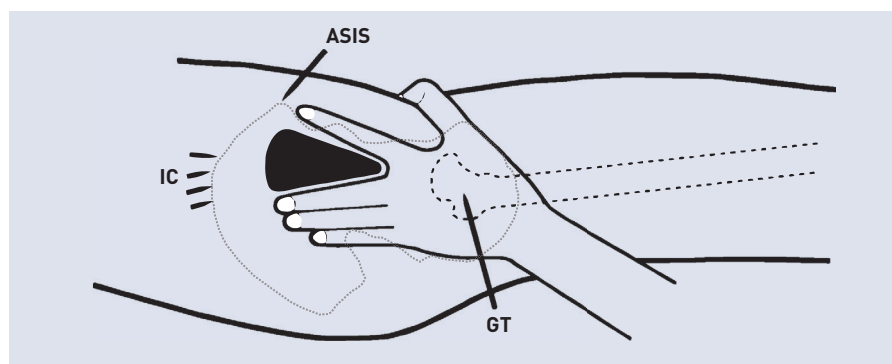
Email: a.mirjalili@auckland.ac.nz

Submitted: 22 January 2018; Editor's

response: 25 January 2018; final acceptance: 21 February 2017.

©British Journal of General Practice 2018; 68: 392–393.

DOI: <https://doi.org/10.3399/bjgp18X698273>



**Figure 1.** The gluteal triangle (ventrogluteal region).<sup>3</sup> ASIS = anterior superior iliac spine. GT = greater trochanter. IC = iliac crest.

## REFERENCES

- Wallis K, Dovey S. No-fault compensation for treatment injury in New Zealand: identifying threats to patient safety in primary care. *BMJ Qual Saf* 2011; **20**(7): 587–591.
- Mishra P, Stringer MD. Sciatic nerve injury from intramuscular injection: a persistent and global problem. *Int J Clin Pract* 2010; **64**(11): 1573–1579.
- Currin SS, Mirjalili SA, Meikle G, Stringer MD. Revisiting the surface anatomy of the sciatic nerve in the gluteal region. *Clin Anat* 2015; **28**(1): 144–149.
- Davidson LT, Carter GT, Kilmer DD, Han JJ. Iatrogenic axillary neuropathy after intramuscular injection of the deltoid muscle. *Am J Phys Med Rehabil* 2007; **86**(6): 507–511.
- Zhang J, Moore AE, Stringer MD. Iatrogenic upper limb nerve injuries: a systematic review. *ANZ J Surg* 2011; **81**(4): 227–236.
- Mirjalili SA, Muirhead JC, Stringer MD. Ultrasound visualization of the spinal accessory nerve in vivo. *J Surg Res* 2012; **175**(1): e11–e16.

## Competing interests

The authors have declared no competing interests.

## Acknowledgements

Sebastien Barfoot, Department of Anatomy and Medical Imaging, University of Auckland, New Zealand. Professor Mark Stringer, Paediatric Surgeon, Wellington (Figure 1).

## Discuss this article

Contribute and read comments about this article: [bjgp.org/letters](http://bjgp.org/letters)

injections in all age groups are the gluteal triangle and the anterolateral thigh.

## Median nerve at the antecubital fossa

The median nerve controls most of the muscles in the forearm and provides sensory input to the thumb, index and middle fingers. If damaged, patients may be unable to oppose the thumb and have weak wrist and finger flexion. The median nerve enters the cubital fossa medial to the palpable brachial artery.

## Radial nerve at the antecubital fossa

Damage to the radial nerve can leave patients unable to extend their wrist (wrist drop). The radial nerve lies immediately at the lateral border of the cubital fossa, under the brachioradialis muscle.

For venepuncture at the antecubital fossa, the lateral border of the cubital fossa should be avoided. Blind attempts should also be avoided. If it is not possible to identify the median cubital vein, for example, in obesity, an alternative site should be considered or, if available, ultrasound guidance used.

## Ulnar nerve at the medial epicondyle

Damage of the ulnar nerve can result in claw hand deformity and loss of sensation to the little finger. The ulnar nerve can often be palpated as it runs behind the medial epicondyle. If it is not possible to identify the nerve or the tip of the medial epicondyle, steroid injections for medial epicondylitis should be avoided or ultrasound guidance used.

## Median nerve at the wrist (carpal tunnel)

At the distal forearm the median nerve runs between the two visible tendons, the palmaris longus and flexor carpi radialis. The palmaris longus may be absent in up to 25% of people. The recommended safe zone for carpal tunnel steroid injections is a 9 mm zone located 8 mm radially (laterally) from the pisiform. Alternatively, the hook

of hamate can be used as a palpable landmark. The safe zone lies radial (lateral) to the hook, but not more than 5 mm radial to it. The ulnar artery and nerve lie ulnar (medial) to the hook. Supplementary material in the form of short educational videos on nerve anatomy to guide safer interventions in primary care are available on request from authors.

## Spinal accessory nerve in the neck

Accessory nerve injuries can be debilitating resulting in paralysis of the trapezius, drooping of the shoulder, loss of full abduction, winging of the scapula, and pain. It is estimated that up to 8% of procedures in the posterior triangle of the neck are associated with accessory nerve injury, mostly caused by skin lesion removal and lymph node biopsy. The spinal accessory nerve has a superficial and highly variable course in the posterior triangle of the neck.<sup>6</sup> Landmarks in this region cannot be relied on to avoid nerve injury. Patients requiring procedures in the posterior triangle of the neck should be referred. Supplementary material in the form of short educational videos on nerve anatomy to guide safer interventions in primary care are available on request from authors.

## Common fibular nerve in the leg

Injury to the fibular nerve can result in foot drop. The common fibular nerve is prone to injury at the fibular neck as it curves superficially lateral to the fibula.

## CONCLUSION AND RECOMMENDATIONS

Avoidable iatrogenic nerve injuries are a persisting problem in primary care, most commonly caused by venepuncture, intramuscular injection, and steroid injection. Nerve injuries may be difficult to diagnose in babies and young children.

Modern radiological evidence suggests that the safest sites for intramuscular injections in all age groups are the gluteal triangle (ventrogluteal region) and the anterolateral thigh. The lateral border of the antecubital fossa should be avoided for venepuncture, as should blind attempts. If it is not possible to identify landmarks, for example, in obesity, ultrasound guidance is recommended.

## Funding

Funded by School of Population Health, University of Auckland.

## Provenance

Freely submitted; externally peer reviewed.