

ERRATA

It is regretted that the captions appearing below figures 3, 4, 6 and 7, printed opposite page 351, *Journal* 59, were incorrect. Readers are asked to substitute this page for that referred to above. On page 353—section headed “autopsy”: line 13 should read (figures 5 and 6); line 18, (figure 4); line 20, (figure 3); and in line 26 add after “haemosiderin”, (figure 7).

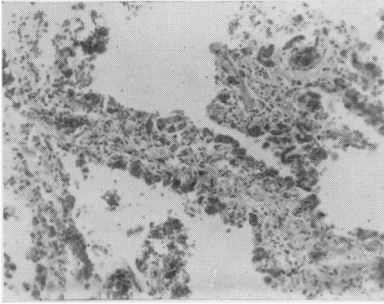


Figure 2.
Lung Section. Dilated capillaries on the surface of the thickened fibrotic alveolar wall (H. and E. $\times 150$)

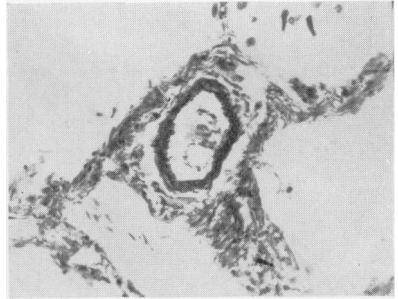

Figure 3.
Lung Section. Pulmonary arteriole showing distinct muscular media with internal and external elastic laminae indicating grade 1 hypertensive pulmonary vascular disease. (Elastic/Van Gieson $\times 250$)

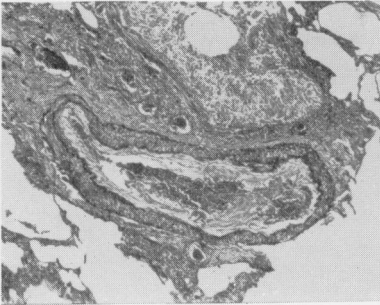


Figure 4.
Lung Section. ‘Muscular pulmonary artery’ showing medial hypertrophy and organized recanalized thrombus. (Elastic/Van Gieson $\times 60$)

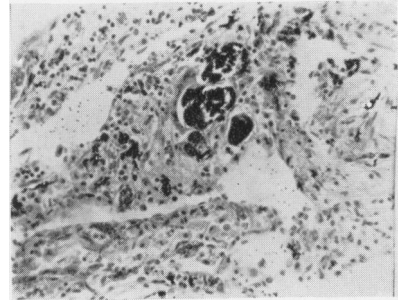


Figure 5.
Lung Section. Focal collection of calcified concretions with surrounding lymphocytes. (H. and E. $\times 250$)

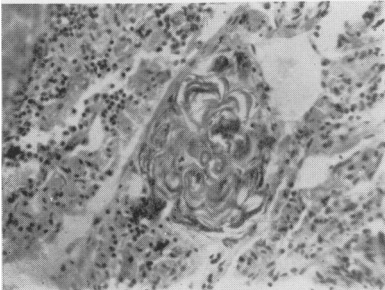


Figure 6.
Lung Section. Focal collection of laminated concretions with surrounding lymphocytes. (H. and E. $\times 250$)

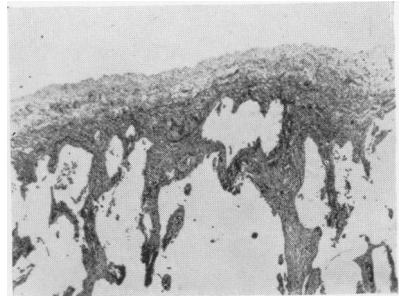


Figure 7.
Lung Section. ‘Interstitial fibrosis and pleural thickening with compensatory emphysema.’ (Elastic/Van Gieson $\times 35$)