

## Injuries sustained by recipients of 'roly-poly kissograms'

J C W JOLLEYS

J V JOLLEYS

### Introduction

It has become popular in recent years for celebrants of birthdays, impending matrimony and so on to receive a surprise visit from a 'kissogram'. A variation on this theme is the 'roly-poly kissogram' — a visit from a woman of substantially greater body mass index than the accepted norm for women.

We report a series of three cases where injury was sustained by the recipient. The injuries were similar to those which might be suffered during sporting activity.

### Case 1

A man celebrating his fiftieth birthday suffered a crush injury to the right costal margin while being embraced by a roly-poly kissogram. On examination there was localized swelling and tenderness over the right costochondral cartilage, but no fracture. He was in pain for six weeks and for four weeks was unable to perform his duties as a publican — lifting barrels and using a beer pump.

Costal cartilage injuries are common in rugby football as a result of crush force injuries associated with a hard body tackle.<sup>1,2</sup>

### Case 2

A 21-year-old man attending his stag party two nights prior to his marriage sustained an iliopsoas muscle strain while lifting with bravado a particularly heavy kissogram. He presented with a limping gait and pain in the right groin region, which he attributed to herniation. On examination there was no hernia, but tenderness in the groin area exacerbated by resisted hip flexion was noted. Although symptoms lasted for two weeks and required medication with a non-steroidal anti-inflammatory drug, there was no report as to whether any activities were curtailed.

Iliopsoas strains are seen in sports which involve either repetitive or forced flexion of the hip and lifting, for example weightlifting.<sup>3,4</sup>

### Case 3

On his twenty fifth birthday a man received a roly-poly kissogram and an undisplaced fracture of the nose with epistaxis. He required hospital treatment from an accident and emergency department to control his epistaxis. The injury occurred when the kissogram leant over to embrace him, overbalanced and knocked him off his bar stool, resulting in direct trauma to the nose against the lady's forearm as she fell from her own bar stool across him.

Nose injuries are common in contact sports, such as rugby football and boxing.<sup>4</sup>

J C W Jolleys, MA, BM, J V Jolleys, BA, MRCP, general practitioners, Belton, Leicestershire.

© *British Journal of General Practice*, 1990, 40, 516-518.

### Discussion

These case reports demonstrate that a variety of injuries can result from the attentions of a roly-poly kissogram. These injuries are similar to those sustained in various sports and the forces involved may be identical to those experienced 'on the field of play'.

Further research is needed to determine the prevalence of injury among recipients of roly-poly kissograms.

### References

1. Walkden L. Immediate post injury considerations in games. In: Reilly T (ed). *Sports fitness and sports injuries*. London: Faber, 1981: 251.
2. Conn HJ, Hardy JD, Fair WR, Natterville RE. Thoracic trauma: analysis of 1022 cases. *J Trauma* 1963; 3: 22-40.
3. McLatchie GR. *Essentials of sports medicine*. Edinburgh: Churchill Livingstone, 1986: 190.
4. Peterson L, Renstrom P. *Sports injuries*. London: Martin Dunitz, 1986.

### Address for correspondence

Dr J V Jolleys, The Surgery, 1 Mill Lane, Belton, Loughborough, Leicestershire LE12 9UJ.

## Ecchymosis hominis circulare: a rare phenomenon?

R HUTCHINSON

S P WILLIAMS

### Case report 1

A 29 year old male europid, previously fit and well, presented with an exactly circular, macular area of blue discoloration in the midline of his forehead (Figure 1). The lesion was 4 cm in diameter, solitary and painless. The patient was suffering acute embarrassment but was otherwise systemically well with a slight tachycardia.

Although the patient was initially evasive, it became apparent on careful questioning that the patient had applied a suction device to his forehead in a futile attempt to entertain his young daughter by impersonating a Dalek.<sup>1</sup> The lesion was sustained

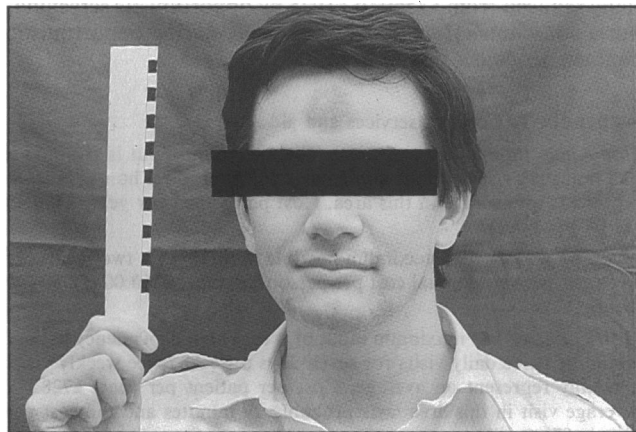


Figure 1. A classical example of ecchymosis hominis circulare.

R Hutchinson, FRCS, surgical registrar, East Birmingham Hospital. S P Williams, MRCP, paediatric registrar, Birmingham Childrens Hospital. Submitted: 20 August 1990; accepted: 20 September 1990.