

Achilles tendon rupture:

how to avoid missing the diagnosis

INTRODUCTION

Over recent months, the authors of this paper have seen an increase in the number of patients with a delayed or missed diagnosis of ruptured Achilles tendon presenting to their orthopaedic clinics. Many subscribe to the view that any delay in diagnosis of more than 24 hours is a relative indication for surgery. In a recent review of negligence claims in foot and ankle surgery, it was shown that delayed or missed diagnosis of ruptured Achilles tendon represented the third highest claim, with an average of £56 900 per case.¹

Rupture of the Achilles tendon is a common injury, with approximately 4500 patients seeking medical help every year in the UK.²⁻⁴ Most cases of Achilles tendon rupture are traumatic sports injuries. The typical age of patients is 29–40 years with a male-to-female ratio of nearly 20:1.

HISTORY

A sudden pain in the back of the leg, with an audible snap, is the classic story in Achilles tendon rupture. Patients will often think that they have been hit directly in the calf; it is very rare for there to be prior symptoms from the tendon.

Points to remember

- Patients who think they sprained their ankle or calf *may* have ruptured their Achilles tendon.
- Patients who rupture their Achilles tendon have usually not had any previous Achilles symptoms.

EXAMINATION

Look. Swelling and bruising are variable and not reliable.

Feel. Tenderness is very likely but may not be at the precise level that is expected. A gap in the tendon is frequently not evident (local swelling masking this).

Move. Because several other tendons (long toe flexors, tibialis posterior, peronei, plantaris) pass from the calf to the foot,

some active plantar movement of the ankle is usually still possible. Passive movement is affected by pain but not actually limited. Active dorsiflexion is unaffected.

Points to remember

- Patients with rupture of the Achilles tendon can still walk.
- Patients with rupture of the Achilles tendon can still actively move the ankle up and down.
- Patients with an Achilles tendon rupture may even manage to stand on tiptoes (on both feet together — though not on the injured limb alone).
- Patients with an Achilles tendon rupture will not always have a palpable gap in the tendon.

Special tests

Clinicians will never be falsely reassured by these history and examination findings if they remember to assess for Achilles tendon rupture specifically with the Simmonds' calf squeeze test.

Simmonds' test, first described in 1957⁵ by Franklin 'Sam' Simmonds, and subsequently by Thompson in 1962,⁶ should be understood and remembered by all medical and physiotherapy practitioners. It is an excellent test, perhaps the closest that there is to 'the perfect clinical test'.

Technique

The Simmonds' calf squeeze test is best performed with the patient kneeling on a chair or bench, or lying prone on an examination couch. In either position, both feet and ankles must be free and dangling unsupported (Figures 1 and 2). Gently squeezing the normal leg, over the bulky part of the calf muscle, will make the foot move into plantar flexion (Figures 3 and 4). When the test is repeated on the injured side the foot will not move if there is a fresh rupture of the Achilles tendon. This is because the calf muscle (gastrocnemius-soleus complex) is no longer connected to the foot.

Robert PR Boyd, BM, BSc, MRCS, ST6, Trauma & Orthopaedics, Ashford & St Peter's Hospital, Chertsey. **Richard Dimock**, MBBS, CT1, Trauma & Orthopaedics; **Matthew C Solan**, FRCS (Orth), consultant orthopaedic surgeon (foot & ankle), Royal Surrey County Hospital, Egerton Road, Guildford, Surrey. **Edward Porter**, MBBS, GP, North Baddesley Surgery, Norton Welch Close, Fleming Avenue, North Baddesley, Hampshire.

Address for correspondence

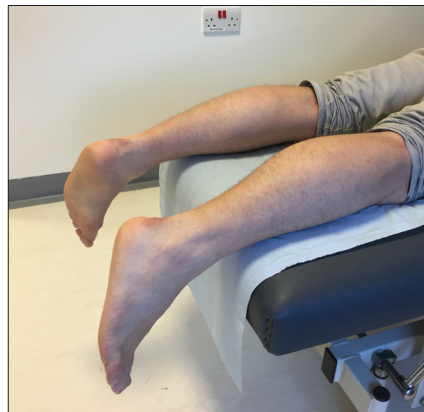
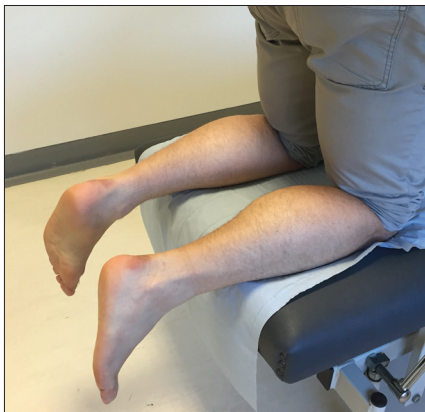ST6 Trauma & Orthopaedics, Ashford & St Peter's Hospital, Chertsey, KT16 0PZ, UK.

E-mail: robertboyd@doctors.org.uk

Submitted: 6 May 2015; **final acceptance:** 25 August 2015.

©British Journal of General Practice 2015; 65: 668–669.

DOI: 10.3399/bjgp15X688069



Figures 1 and 2. Position on couch.

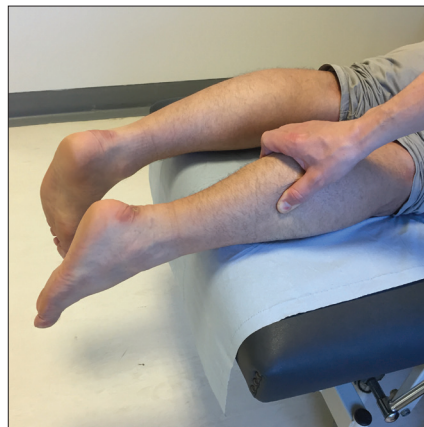
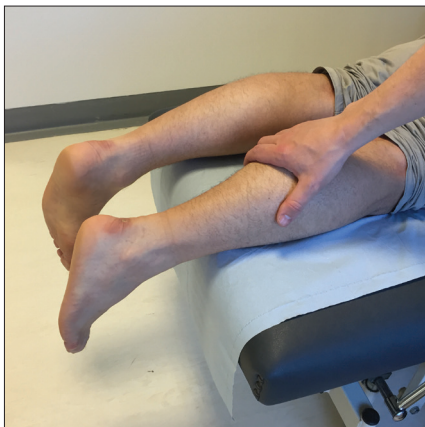
Figure 3 and 4. Pre- and post-calf squeeze.

REFERENCES

1. Ring J, Talbot CL, Clough TM. Clinical negligence in foot and ankle surgery: a 17-year review of claims to the NHS Litigation Authority. *Bone Joint J* 2014; **96-B(11)**: 1510–1514.
2. Leppilahti J, Puranen J, Orava S. Incidence of Achilles tendon rupture. *Acta Orthop Scand* 1996; **67(3)**: 277–279.
3. Suchak AA, Bostick G, Reid D, et al. The incidence of Achilles tendon ruptures in Edmonton, Canada. *Foot Ankle Int* 2005; **26(11)**: 932–936.
4. Maffulli N, Waterston S, Squair J, et al. Changing incidence of Achilles tendon rupture in Scotland: a 15-year study. *Clin J Sport Med* 1999; **9(3)**: 157–160.
5. Simmonds FA. The diagnosis of the ruptured Achilles tendon. *Practitioner* 1957; **179(1069)**: 56–58.
6. Thompson TC. A test for rupture of the tendo achillis. *Acta Orthop Scand* 1962; **32**: 461–465.

Documentation of result

The test is positive if, on the injured side, the foot does not move when the calf is squeezed. To avoid confusion it is best to document the result in longhand: 'the foot does not move when calf is squeezed (Achilles rupture)' or 'symmetrical left = right foot movement on calf squeeze test (no Achilles rupture)'.

Imaging studies

In the acute setting there is no need for any imaging at all for the purpose of establishing the diagnosis; scans may even serve to confuse and falsely reassure. A radiological report of a 'partial tear' should be an assumed complete Achilles tendon rupture, if this fits with the clinical history. Like all rules, there are of course (very rare) exceptions, but by far the best and safest approach is to assume the worst and refer the patient for further assessment.

Caveats

Exceptionally rare situations where there may be a false-negative result to the Simmonds' calf squeeze test do exist.

A patient who has had joint fusion surgery to the hind foot, or has a very stiff ankle

from arthritis or trauma, will have a false-negative result on performing the calf squeeze test. Severe calf muscle wasting from neurological causes has the potential to produce the same error. Prior surgery, such as an Achilles tendon lengthening (for example, with treatment for club-foot), presents a further possible exception to the rule.

More relevant is the question of a delay after injury. A neglected tendon rupture will heal, albeit at an elongated length, giving rise to long-term weakness. There is no evidence to clarify the time interval between injury and the return of (some, though reduced) foot movement when Simmonds' test is performed.

Simmonds' test cannot be relied upon in chronic cases, though an excellent test for 'chronic rupture' is the hyper-dorsiflexion test. If the Achilles tendon has healed without any treatment then it will be elongated, and the affected ankle exhibits a greater range of passive dorsiflexion than the normal ankle (where the Achilles tension limits motion before the bony anatomy does).

LEARNING SUMMARY

- The calf squeeze (Simmonds' test) should be performed, and the findings clearly documented, in all ankle injuries and 'calf sprains'.
- 'There is no such thing as a partial tear.'
- Imaging studies are not required to make the diagnosis in the acute situation, and frequently offer false reassurance.
- Patients with an acute rupture of the Achilles tendon can still walk and move the ankle, using other parts of the calf muscle complex.
- Although the debate regarding operative versus non-operative treatment is unresolved, the need for prompt recognition of this injury is paramount.

Provenance

Freely submitted; not externally peer reviewed.

Competing interests

The authors have declared no competing interests.

Discuss this article

Contribute and read comments about this article: www.bjgp.org/letters